

# Review of 15 cases of pemphigus foliaceus in horses and a survey of the literature

S. ZABEL, R. S. MUELLER, K. V. FIESELER, S. V. BETTENAY, J. D. LITTLEWOOD, R. WAGNER

**The records of 15 horses with pemphigus foliaceus diagnosed on the basis of their history, clinical signs, histopathology and the exclusion of differential diagnoses were evaluated with respect to the age of onset, the clinical signs and the diagnostic tests used. There was no apparent breed predisposition. The horses' mean age was nine years, with a range from three months to 25.5 years, three were foals up to six months old and eight were nine years old or older. The most frequent lesions were scaling in 11, crusting in 10 and alopecia in 10, and they appeared most commonly on the face, neck and trunk, in 10 horses for each of these sites. The extremities were involved in nine of the horses, pruritus occurred in seven, and four of the horses had pustules. The clinical signs mostly corresponded with those described in previous reports, but signs of pain were not a prominent feature. Acantholytic cells were identified cytologically in four of six of the horses.**

*Veterinary Record* (2005)  
157, 505-509

**S. Zabel**, DVM, MS,  
**R. S. Mueller**, DrMedVet,  
DrHabil, DipACVD,  
DipECVD, FACVSc,  
MACVSc,  
**S. V. Bettenay**, BVSc,  
MACVSc, DipEd, DipECVD,  
FACVSc,  
**K. V. Fieseler**, DVM,  
Veterinary Teaching  
Hospital,  
College of Veterinary  
Medicine and Biomedical  
Sciences, Colorado State  
University, Fort Collins,  
CO 80523, USA  
**J. D. Littlewood**, BVSc,  
MA, PhD, DVD, DVR,  
MRCVS,  
Veterinary Dermatology  
Referrals, 2 Waterbeach  
Road, Cambridge CB4 8EA  
**R. Wagner**, DrMedVet,  
College of Veterinary  
Medicine, University of  
Vienna, Vienna, Austria

Dr Mueller's present  
address is Medizinische  
Tierklinik, Ludwig-  
Maximilians-Universität  
München,  
Veterinärstrasse 13, 80539  
München, Germany

Dr Bettenay's present  
address is Bahnhofstrasse  
14, 82041 Oberhaching,  
Germany

Dr Wagner's present  
address is Pommersdorf  
14, 3820 Raabs/Thaya,  
Austria

PEMPHIGUS foliaceus is the most common autoimmune skin disease of horses and was first described by Barnick and Gutzeit (1891). It has been reported in horses from two months to 25 years of age (Laing and others 1992, Vandenabeele and others 2003). The lesions at first usually affect the head and lower extremities (von Tscharnner and others 2000, Scott and Miller 2003), but they often spread to other areas within one to three months (von Tscharnner and others 2000, Scott and Miller 2003). The ventral abdomen and lower extremities may develop pitting oedema (Manning 1983, Scott 1989, White 1992), especially of the hindlimbs (von Tscharnner and others 2000). Systemic signs such as fever, depression, loss of appetite, lethargy and weight loss, and clinicopathological findings such as non-regenerative anaemia, neutrophilia and hypoalbuminaemia, have also been reported (Manning 1983, Scott and others 1987, Scott 1989, White 1992). The primary lesions of pemphigus foliaceus are fragile vesicles, bullae and pustules, but most horses develop secondary lesions such as erosions, epidermal collarettes, crusts, alopecia, exudation and scaling (Scott and Miller 2003).

A definitive diagnosis can be made by a combination of tests including direct smears, skin biopsies, immunofluorescence or immunohistochemical tests, and by ruling out differential diagnoses such as dermatophytosis (Scott and Miller 2003). Multiple biopsies, especially from intact pustules and/or crusted areas, or the crusts themselves, are most valuable (von Tscharnner and others 2000) and classically show subcorneal and/or intraepidermal pustules associated with marked acantholysis (Scott 1989, Yaeger and Scott 1993, von Tscharnner and others 2000).

The aim of this retrospective study was to evaluate the age of onset and clinical signs of pemphigus foliaceus in 15 horses and the value of the tests used to diagnose the disease, and to compare the findings with previous reports.

## MATERIALS AND METHODS

The medical records of horses examined at the Veterinary Teaching Hospital, Colorado State University (CSU), from February 1991 to February 2002, were searched electronically for diagnoses of pemphigus foliaceus, and other dermatology referral practices were contacted with a request to participate in the study. A questionnaire requesting information about the characteristics of the affected horses, their housing conditions, dates of visits, history, the results of physical examinations and diagnostic tests, and the treatments given, was

distributed to all interested parties and the completed questionnaires were evaluated. If the information was consistent with a diagnosis of pemphigus foliaceus, the original haematoxylin and eosin-stained biopsy slide or a re-cut of the formalin-fixed tissues was re-evaluated by a dermatopathologist to verify the diagnosis. To determine whether there was a breed predisposition, a comparison was made of the breeds affected with the hospital population of horses examined at CSU by using chi-squared and Fisher's exact tests.

A literature search was conducted using the CAB Abstracts, PubMed and MEDLINE databases, searching for the user string '(horse OR horses OR equine) and (pemphigus OR pemphigus foliaceus)', and additional references were obtained from the reports identified and from textbooks. In all of the studies included in the summary of this literature review the diagnosis of pemphigus foliaceus had been confirmed by histopathology.

## RESULTS

The reports on 10 horses examined by the dermatology service at CSU, two examined by the dermatology service of the University of Edinburgh, two by Veterinary Dermatology Referrals in Cambridge, and one examined by the dermatology service of the University of Vienna, were evaluated.

The age at which the disease developed, and the breed, sex and colour of the horses, are shown in Table 1. Nine of the horses lived on a combined paddock and stable, including the four horses from Great Britain, two lived on a paddock, and one was stabled; no information was available for the other three horses.

In one of the horses the lesions first appeared in January, in two they appeared in February, in two in March, in two in May, in two in July, in two in September, in three in October and in one in November. Thus, four of them showed the first clinical signs in spring (March, April and May), two in summer (June, July and August), six in autumn (September, October and November) and three in winter (December, January and February). In two of the horses the lesions recurred each summer, and in one horse they waxed and waned irrespective of the season.

The average interval between the first onset of lesions until the horses were first examined by a specialist was 8.6 months, with a range from one to 32 months; for two of the horses no information was available. Two of the horses were reported to be depressed when first examined and two were bright and alert, but there were no special comments about the attitude

**TABLE 1: Age of disease onset, breed, colour and sex of 15 horses and ponies with pemphigus foliaceus**

Horse	Age at onset	Breed	Colour	Sex
1	9 years	Pony	Grey	G
2	6 months	American paint	White/sorrel	M
3	12 years	Welsh pony	Chestnut	F
4	17 years	Quarter horse	Chestnut	G
5	7 years	Spanish mustang	Buckskin	F
6	15 years	Warmblood	Buckskin	G
7	3 months	American paint	Buckskin	F
8	11 years	Quarter horse	Black	F
9	10 years	Quarter horse	Buckskin	F
10	3 months	Quarter horse	Black	M
11	5 years	Quarter horse	Grey	G
12	12 years	Arab	White	F
13	25.5 years	Quarter horse	Palomino	G
14	2 years	Welsh pony	Grey	G
15	7 years	Shire/thoroughbred cross	Bay	F

G Gelding, M Male, F Female

**TABLE 2: Clinical signs observed in 15 horses and ponies with pemphigus foliaceus when they were first examined by the local veterinarian and when they were examined by a specialist**

Lesion/sign	Number of horses affected	
	Local veterinarian	Specialist
Pustules	0	4
Papules	2	1
Collarettes	0	2
Crusts	7	10
Scales	2	11
Matted hair	0	3
Alopecia	5	10
Erosions	0	1
Hyperpigmentation	0	2
Lichenification	0	2
Oedema	4	1
Urticaria	3	1
Swelling	2	0
Loss of appetite	1	0
Lethargy	1	0
Hyperaesthesia	1	2
Pruritus	4	7
Pain	3	0

or activity of the other 11. The temperature and pulse and respiration rates of all 15 horses were within normal limits. The lesions and clinical signs observed by the referring veterinarian and by the specialist are listed in Table 2.

When first examined, a complete blood count was made in two of the horses, biopsies were taken from two, a bacterial culture was made from two, skin scrapings were taken from one, a fungal culture was made from one and one was put on a diet trial. The skin scrapings and cultures were negative, and the blood counts were normal. The histopathological results from one of the biopsies was consistent with hypersensitivity, but the result of the other is not known.

Ten of the horses were treated orally with antibiotics, seven with topical antiseptic, four with antihistamines, four with glucocorticoids, three with griseofulvin, two with a shampoo, one with non-steroidal anti-inflammatory agents, one with paraffin, one with ivermectin, one with thyroid supplementation, one with a change of diet, one with sunscreen and one was brought indoors. Two of the horses treated with glucocorticoids, one of the horses treated with antihistamines and the two that were treated with oral antibiotics initially improved slightly, but the other treatments had no effect.

The distribution of the lesions is shown in Fig 1; the alopecia and scaling in a six-month-old American paint colt is shown in Fig 2, and one of its overgrown hooves is shown in Fig 3. Pruritus affected seven of the horses, and was mild in three, moderate in two and severe in two. Four of the other

horses were not pruritic, but no information was available for the other four.

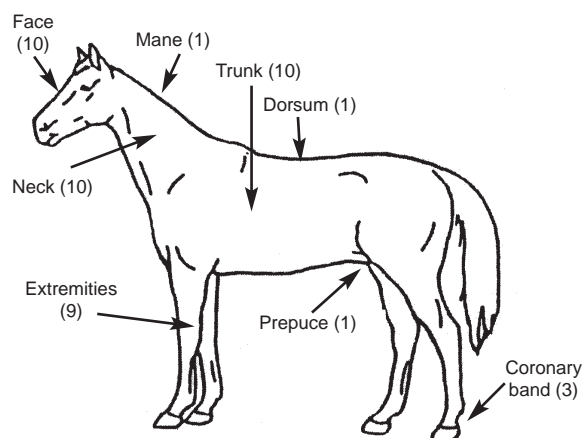
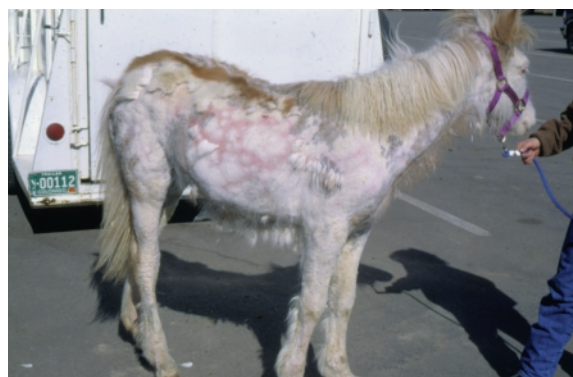The diagnostic tests applied by the specialists are listed in Table 3. One of the 10 fungal cultures was positive for *Microsporium nanum*, but the others were negative. In the horse with the positive fungal culture, no fungal elements were visible in a biopsy; it responded to immunosuppressive doses of prednisolone (2 mg/kg) after it had failed to respond to topical antifungal treatment.

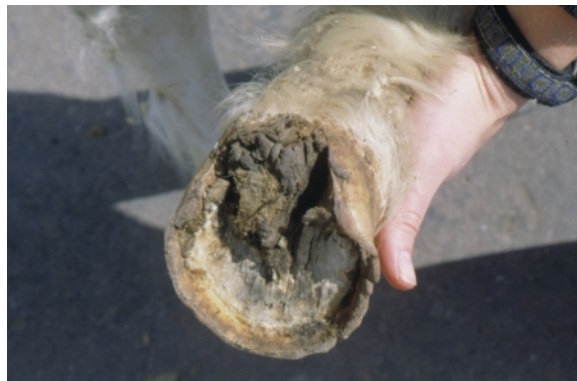Three of the horses had a mild neutrophilia. Biochemical changes included hyperglobulinaemia in three, hyperfibrinogenemia in three, hypoalbuminaemia in two and a mild increase in serum activity of liver enzymes in two. The results of the culture/susceptibility and skin scrape tests were negative. The result of the adrenocorticotropic hormone (ACTH) stimulation test was normal.

Acantholytic cells were identified in four of the six horses in which cytology was evaluated; another showed neutrophils and intracellular cocci, and the last showed no abnormalities.

In most cases multiple sites were biopsied. The histopathological findings were consistent with pemphigus foliaceus, revealing serocellular crusting with acantholytic keratinocytes in all 15 horses, and intraepidermal pustules containing predominantly neutrophils and acantholytic cells in seven of them. The dermal infiltrate was predominantly lymphocytic. Fungal stains were negative in all the specimens.

Three of the horses were initially treated with 2 mg/kg per day of prednisolone, and nine were treated with prednisone at 2 mg/kg per day and one at 1 mg/kg per day. The lesions on one pony initially went into remission without treatment, but

**FIG 1: Numbers of horses and ponies among the 15 with pemphigus foliaceus in which different body sites were affected****FIG 2: Alopecia and scaling in a six-month-old American paint colt with pemphigus foliaceus. Reproduced with permission from Mueller (2005)**



**FIG 3: Overgrown hoof of the colt in Fig 2. Reproduced with permission from Mueller (2005)**

when they recurred it was treated intramuscularly with a combination of 2.7 mg/kg per day prednisolone and sodium aurothiomalate (Myocrisin; Aventis Pharma) at 160 mg weekly for two weeks and then 150 mg weekly.

Follow-up information was available for seven of the 15 horses. One horse had been euthanased owing to financial constraints, and one foal had died of pneumonia. One horse had responded well to prednisone and two had responded to prednisolone at 2 mg/kg per day. The horse on prednisone relapsed when the dose was gradually reduced and it had to be maintained on the initial dose; in the other two horses, the maintenance doses were reduced. The two-year-old pony received sodium aurothiomalate injections for 16 months and, at the time of writing, had been in remission for 10 years without the need for any treatment.

The owners of the remaining horse did not agree with the diagnosis of pemphigus foliaceus and changed veterinarians and treatments several times.

## DISCUSSION

Pemphigus foliaceus is an autoimmune disease that is directed against desmosomes in the stratified squamous epithelium and leads to the loss of intracellular cohesion, acantholysis and blister formation within the epidermis (Halliwell 1979, Laing and others 1992, Scott and Miller 2003). In human beings and dogs, desmoglein I, a glycoprotein, has been detected as the major pemphigus foliaceus antigen, but no similar information is available for horses (Suter 1998, Anhalt 1999).

The disease has been described in human beings, dogs, cats, goats and horses (Halliwell 1979, Johnson and others 1981, Manning and others 1981). It is the most common autoimmune skin disease of horses (Scott and others 1987, von Tschärner and others 2000). Johnson and others (1981) described the histological and immunopathological changes caused by the disease in a horse, and since then there have been 12 reports of single cases, two reports of two cases and one report of eight cases in horses; this last publication (Scott and others 1987) focused on the histological and immunological effects of the disease and gave therapeutic information. Vandenabeele and others (2003) reviewed 19 cases in horses.

The age of the horses in previous reports ranged from two months (Laing and others 1992) to 25 years (Vandenabeele and others 2003), which is consistent with the findings in the present study, although one quarter horse gelding in the present study showed the first signs of disease at 25.5 years of age, which is, to the authors' knowledge, the latest age of onset described. In this study three of the horses were six months old or younger, eight were nine years old or older, and the other four horses were of intermediate ages. In the literature, age information is available for 28 horses; 10 of them became diseased at six months of age or younger, and 18 were nine years old or older.

**TABLE 3: Diagnostic tests applied to 15 horses with pemphigus foliaceus when they were examined by a specialist**

Diagnostic test	Number of horses
Fungal culture	10
Complete blood count	9
Blood chemistry	7
Direct smear	6
Culture/susceptibility tests	4
Skin scrape	2
Adrenocorticotrophic hormone stimulation test	1

Scott and others (1983), Pascal and others (1995) and von Tschärner and others (2000) did not indicate whether there was any breed or sex predilection, or any indication of seasonality in the disease. In a study by Scott (1989), Appaloosas were over-represented. Comparisons by chi-squared and Fisher's exact tests of the 15 horses in the present study with the general population of horses examined at CSU revealed no breed predilection. At the time of writing, 13 quarter horses, seven thoroughbreds and two thoroughbred crosses, seven warmbloods, seven Arabians, four standardbreds, four Appaloosas, three mixed-breed horses, three Welsh ponies, three Morgans and one other pony, two American paint horses and one Tennessee walker horse, and one Spanish mustang have been reported as having the disease. They were distributed all over the USA, Europe and Australia, and it is therefore difficult to comment on breed predispositions. Evidence of regional differences may be that six of the seven warmbloods and one of the thoroughbred crosses were in Europe and the other thoroughbred cross was in Australia. Before this study, pemphigus foliaceus had been reported in only one pony, a Welsh pony (Griffith 1987). The three ponies in the present study lived in Great Britain; two were Welsh ponies but the breed of the other is unknown.

As in previous reports, no differences in coat colour were detectable in the 15 horses, and there appeared to be no sex predisposition; of the previous 43 reported cases, 17 were mares, 20 were geldings and six were stallions, and in the present study seven of the 15 horses were female, six were geldings and there were two colts, three and six months old when they were affected.

In a retrospective study of 19 cases of pemphigus foliaceus, Vandenabeele and others (2003) reported a higher prevalence of the disease between September and February, but this was not the case in the present 15 cases. Scott (1989) and White (1992) reported that the signs of the disease became more severe in warm, humid and sunny weather. In the present study, one horse, a warmblood, did not show clinical signs during the winter but deteriorated every summer when it was taken on to a high-altitude pasture; when it was returned to the valley permanently, no further clinical signs were observed. The increased exposure to UV light at high altitude may have been involved. In a second horse, a research pony, the clinical signs worsened in summer and when it was stressed by being handled or anaesthetised. Pemphigus foliaceus may be triggered by factors such as stress, drug administration, systemic disease or hypersensitivity to *Culicoides* species (White 1992, von Tschärner and others 2000), and the disease may wax and wane (Fadok 1995). Von Tschärner and others (2000) suggested that hereditary factors may predispose horses to pemphigus foliaceus but, because the disease has been recorded in unrelated horses living in the same area, they accepted that environmental or infectious factors may play a role. Hypothyroidism was reported to be associated with pemphigus foliaceus in horses (Peter and others 1981, Griffith 1987).

The head and lower extremities have been reported as commonly affected sites (von Tschärner and others 2000,

Scott and Miller 2003). Scott (1983) reported that the ventrum was a predilection site in eight affected horses, but the disease frequently spreads to other areas within one to three months (von Tscharnner and others 2000, Scott and Miller 2003). The coronary band may show changes and may be the only affected site (Fadok 1995, von Tscharnner and others 2000), and the prepuce or the mammary glands may also be affected (Johnson 1997, Scott and Miller 2003). Pitting oedema of the lower extremities and the ventral abdomen has been observed in over 50 per cent of the cases (Manning 1983, Scott 1989, White 1992) and may be the only initial sign of disease (Scott and others 1983, Schulte and others 1989, von Tscharnner and others 2000, Scott and Miller 2003). Urticaria can occur weeks before classical lesions such as pustules and/or crusts develop (von Tscharnner and others 2000). The 15 horses in the present study were examined by the specialist on average nine months after the onset of the clinical signs. At that time, they showed lesions most commonly on the face, neck, trunk and extremities, as in earlier reports (von Tscharnner and others 2000, Scott and Miller 2003). The coronary band was involved in only three cases, one of which initially showed signs of pain when its coronary bands and heels were touched. Later on, crusty lesions limited to the coronary bands and heels developed. Lesions on the prepuce were reported in one horse and six were reported to have oedema and swelling. One case showed signs of urticaria, and swelling was reported in two cases, but urticaria was not the only clinical sign in any of the horses. Some authors state that affected horses may only occasionally show signs of pruritus but more often show signs of pain (von Tscharnner and others 2000, Scott and Miller 2003). However, when the 15 horses were examined by the referring veterinarians, four showed signs of pruritus and three showed signs of pain; when they were examined by the specialists, more than half of them showed signs of pruritus to various degrees.

The primary lesions of pemphigus foliaceus are vesicles, bullae and pustules, lesions that are fragile and short lived. Most often horses develop secondary lesions such as erosions, epidermal collarettes, crusts, alopecia and scaling (von Tscharnner and others 2000, Scott and Miller 2003). Von Tscharnner and others (2000) describe crusted papules, best seen in lightly haired or hairless skin adjacent to mucocutaneous junctions such as the nostrils, eyelids or lips, as the most common initial sign. In the present study, primary lesions such as papules were only rarely recorded by the referring veterinarian, but the specialist recorded pustules and papules in four of the horses, and most of the horses had secondary lesions such as crusts, scales and alopecia. These findings are consistent with previous reports (Scott and others 1987, von Tscharnner and others 2000).

In over 50 per cent of previous cases, systemic signs such as fever, depression, anorexia, lethargy and weight loss (Manning 1983, Scott 1989, White 1992), and non-regenerative anaemia, neutrophilia, hypoalbuminaemia, high levels of alkaline phosphatase and fibrinogen, and hyperglobulinaemia have been reported (George and White 1984, Day and Penhale 1986, Edmund and Frevert 1986, Scott and others 1987). In contrast, most of the horses in the present study were in good body condition and only a few showed systemic signs.

The disease often involves the mucocutaneous junctions, but the mucous membranes are less often involved (von Tscharnner and others 2000). Erosions of the oesophagus and the oesophageal zone of the stomach were observed in one horse (Wohlsein and others 1993), and the mucous membranes of the lips and anus were involved in another case (Wohlsein and others 1994). George and White (1984) described a horse with ulcerative lesions of the lips, eyes, vulva and tongue. In contrast, none of the 15 horses showed lesions of the mucocutaneous membranes.

Differential diagnoses of pemphigus foliaceus in horses include diseases characterised by scaling and crusting. When they were first examined by the general practitioners, most of the horses were treated for bacterial and/or fungal infections. In some horses diagnostic tests were used to rule out ectoparasites, fungal infections, food hypersensitivity and systemic disease, and biopsies were taken from two of them. At referral, the most common diagnostic procedures included skin biopsies, fungal cultures, blood counts, biochemical tests, and culture and sensitivity tests. The one positive fungal culture revealed *M nanum*, which was considered to be a contaminant, because biopsies and special fungal stains did not show evidence of fungal disease and the horse did not respond to topical antifungal medication, but did respond to immunosuppressive doses of prednisolone. Neutrophilia was the only abnormal haematological result observed; it has been reported in horses with pemphigus foliaceus, and is most probably a sign of inflammatory dermatitis. Hyperglobulinaemia, hyperfibrinogenaemia and hypoalbuminaemia were other findings. One of the two horses with high activities of liver enzymes was a foal with pneumonia; the cause of the problem was not evaluated and the foal died of the pneumonia. The other horse was a nine-year-old pony with no history of systemic disease.

Tests that have been reported to be useful in the diagnosis of pemphigus foliaceus in horses include direct smears, skin biopsies and immunofluorescence or immunohistochemical testing (Scott and Miller 2003). A cytological examination of samples from crusted areas or intact pustules may show large numbers of neutrophils and acantholytic cells, but similar findings may be observed in other diseases such as bacterial pyoderma (Scott 1994, von Tscharnner and others 2000); however, they contribute towards a diagnosis, which should be verified by a histopathological evaluation. To the authors' knowledge, there is no information about the value of direct smears in the diagnosis of pemphigus foliaceus, but the test is quick, inexpensive and easy to perform. The results of this study suggest that it can provide evidence of the disease. The results of culture and sensitivity testing of the bacteria found on direct smears indicate that bacterial secondary infections are uncommon in horses with pemphigus foliaceus.

Several biopsies from intact pustules or crusts are needed to confirm the diagnosis (von Tscharnner and others 2000). The primary histological changes include subcorneal and/or intraepidermal pustules, associated with marked acantholysis (Scott 1989, Yaeger and Scott 1993, von Tscharnner and others 2000); acantholytic cells may either form 'rafts' or remain attached to the roof of the pustule ('cling-ons'). Scott (1989) reported that neutrophils were the major inflammatory cell in two-thirds of the cases, the other cases being characterised by neutrophils and numerous eosinophils. Pustules are very fragile and usually rupture rapidly, forming surface crusting. In the absence of pustules, the large numbers of acantholytic cells and neutrophils in the crusts are often the only diagnostic finding. As acantholysis may also occur in dermatophytosis, special stains and fungal cultures are recommended (Scott and Miller 2003). Histopathology is reported to be far more reliable than immunopathology in the diagnosis of pemphigus foliaceus (Scott and others 1984, Day and Penhale 1986, Griffith 1987, Scott and Miller 2003). The biopsies from all 15 cases in the present study were diagnostic for the disease. Direct immunofluorescence has been reported to be a reliable diagnostic test characterised by the presence of immunoglobulin (Ig) (primarily IgG) and occasionally complement (C3) in the intercellular spaces of stratified squamous epithelium (Rosser and others 1983, Day and Penhale 1986). However, false positive and false negative results can be obtained. Neither immunohistochemistry nor immunofluorescence was needed in this study because the histopathological changes were diagnostic.

The prognosis for horses with pemphigus foliaceus depends on the age of onset. Horses less than a year old seem to have a better prognosis: the disease tends to be less severe, responds better to treatment and may regress spontaneously or not require further medication once it is in remission (Laing and others 1992, von Tscharnner and others 2000, Scott and Miller 2003). However, horses more than five years old have a less favourable prognosis and most require aggressive treatment (von Tscharnner and others 2000). Spontaneous remission is rare, but has been reported (White 1992, Amory and others 1997, von Tscharnner and others 2000, Scott and Miller 2003). A pregnant mare reportedly responded to four months of treatment and its skin lesions did not recur when the treatment was stopped (Messer and Knight 1982). In another case, the clinical signs in a seven-year-old pregnant mare resolved without treatment after it aborted (Scott and others 1983). Some cases are reported to remain in remission for long periods without further treatment (Scott 1989, White 1992) but many do relapse (Scott and Miller 2003).

In horses, pemphigus foliaceus is a disease characterised by scaly or crusty skin, usually on the face, neck and trunk but sometimes becoming more generally distributed. In this study the coronary band was involved less often than in previous studies, few of the horses developed haematological or biochemical changes and none of them showed systemic signs. Their mucous membranes were not involved. There was no evidence of a seasonal increase in the incidence of the disease. In most of the horses cytology was useful in providing diagnostic clues and histopathology confirmed the diagnosis. Too few of the horses were followed up for any conclusions to be drawn about the value of the treatments applied or the prognosis for the horses.

## ACKNOWLEDGEMENTS

The authors thank Dr Ariane Neuber of the University of Edinburgh for participating in the study. Dr Rodney Rosychuk and Dr Stephen White were involved in the care of the horses seen at CSU.

## References

- AMORY, H., BECO, L., DESMECHT, D., JAQUINET, E., VANDENPUT, S. & LOMBA, F. (1997) Pemphigus foliaceus dans l'espèce équine: synthèse et description de 2 cas. *Annales de Médecine Vétérinaire* **141**, 139-148
- ANHALT, G. J. (1999) Making sense of antigens and antibodies in pemphigus. *Journal of the American Academy of Dermatology* **40**, 763-766
- BARNICK, W. & GUTZEIT, R. (1891) Ein Fall von acutem Pemphigus beim Pferde. *Zeitschrift Veterinär Kunde* **3**, 241-244
- DAY, M. J. & PENHALE, W. J. (1986) Immunodiagnosis of autoimmune skin disease in the dog, cat and horse. *Australian Veterinary Journal* **63**, 65-68
- EDMOND, R. J. & FREVERT, C. (1986) Pemphigus foliaceus in a horse. *Modern Veterinary Practice* **67**, 527-530
- FADOK, V. A. (1995) An overview of equine dermatoses characterized by scaling and crusting. *Veterinary Clinics of North America: Equine Practice* **11**, 43-51
- GEORGE, L. W. & WHITE, S. L. (1984) Autoimmune disease in large animals. *Veterinary Clinics of North America: Large Animal Practice* **6**, 79-86
- GRIFFITH, G. (1987) Pemphigus foliaceus in a Welsh pony. *Compendium on Continuing Education for the Practicing Veterinarian* **9**, 347-353
- HALLIWELL, R. E. (1979) Skin disease associated with autoimmunity. *Veterinary Clinics of North America: Small Animal Practice* **9**, 57-71
- JOHNSON, M. E., SCOTT, D. W., MANNING, T. O., SMITH, C. A. & LEWIS, R. M. (1981) Pemphigus foliaceus in the horse. *Equine Practice* **3**, 40-45
- JOHNSON, P. J. (1997) Pemphigus foliaceus in a horse. *Veterinary Allergy and Clinical Immunology* **4**, 131-134
- LAING, J. A., ROTHWELL, T. L. W. & PENHALE, W. J. (1992) Pemphigus foliaceus in a 2-month-old foal. *Equine Veterinary Journal* **24**, 490-491
- MANNING, T. O. (1983) Pemphigus foliaceus. In *Current Therapy in Equine Medicine*. Ed N. E. Robinson. Philadelphia, W. B. Saunders. pp 541-542
- MANNING, T. O., SCOTT, D. W., REBHUN, W. C., SMITH, C. A. & LEWIS, R. M. (1981) Pemphigus-pemphigoid in a horse. *Equine Practice* **3**, 38-44
- MESSER, N. T. & KNIGHT, A. P. (1982) Pemphigus foliaceus in a horse. *Journal of the American Veterinary Medical Association* **180**, 938-940
- MUELLER, R. S. (2005) *Dermatology for the Equine Practitioner*. Jackson, Teton NewMedia. (In press)
- PASCAL, A., SHIEBERT, J. & IHRKE, P. J. (1995) Seasonality and environmental risk factors for pemphigus foliaceus in animals: a retrospective study of 83 cases presented to the Veterinary Medical Teaching Hospital, University of California Davis from 1976 to 1994. Proceedings of the 11th Annual Meeting of the American Academy of Veterinary Dermatology/American College of Veterinary Dermatology. Santa Fe, USA, March 23 to 26, 1995. pp 24-25
- PETER, J. E., MORRIS, P. G. & GORDON, B. J. (1981) Pemphigus in a thoroughbred. *Veterinary Medicine/Small Animal Clinician* **76**, 1203-1206
- ROSSER, E. J., IHRKE, P. J., WHITE, S. D., STANNARD, A. A. & ARDANS, A. (1983) The duration and quality of positive direct immunofluorescence in skin biopsies using Michel's fixative on a case of equine pemphigus foliaceus. *Journal of Equine Veterinary Science* **3**, 14-17
- SCHULTE, A., STADLER, P., OTTO, B., DEEGEN, E. & TRAUTWEIN, G. (1989) Pemphigus foliaceus beim Pferd. *Pferdeheilkunde* **5**, 23-30
- SCOTT, D. W. (1983) Pemphigus in domestic animals. *Clinics in Dermatology* **1**, 141-152
- SCOTT, D. W. (1989) Autoimmune skin diseases in the horse. *Equine Practice* **11**, 20-32
- SCOTT, D. W. (1994) Marked acantholysis associated with dermatophytosis due to *Trichophyton equinum* in two horses. *Veterinary Dermatology* **5**, 105-110
- SCOTT, D. W., MANNING, T. O., SMITH, C. A. & LEWIS, R. M. (1983) Pemphigus and pemphigoid in dogs, cats and horses. *Annals of the New York Academy of Sciences* **420**, 353-360
- SCOTT, D. W. & MILLER, W. H. (2003) Immune mediated disorders. In *Equine Dermatology*. Philadelphia, W. B. Saunders. pp 475-547
- SCOTT, D. W., WALTON, D. K., SLATER, M. R., SMITH, C. A. & LEWIS, R. M. (1987) Immune mediated dermatosis in domestic animals ten years after. *Compendium on Continuing Education for the Practicing Veterinarian* **9**, 424-435
- SCOTT, D. W., WALTON, D. K., SMITH, C. A. & LEWIS, R. M. (1984) Pitfalls in immunofluorescence testing in dermatology. III. Pemphigus-like antibodies in the horse and direct immunofluorescence testing in equine dermatophilosis. *Cornell Veterinarian* **74**, 305-311
- SUTER, M. M. (1998) Autoimmune diseases of domestic animals: an update. In *Advances in Veterinary Dermatology III*. Eds K. W. Kwochka, T. Willemse, C. von Tscharnner. Boston, Butterworth-Heinemann. pp 321-327
- VANDENABEELE, S. I. J., WHITE, S. D., AFFOLTER, V. K. & IHRKE, P. J. (2003) Pemphigus foliaceus in horses: a review of 19 cases. Proceedings of the 18th Annual Meeting of the American Academy of Veterinary Dermatology/American College of Veterinary Dermatology. Monterey, USA, April 9 to 12, 2003. pp 18, 192
- VON TSCHARNER, C., KUNKLE, G. & YAGER, J. (2000) Stannard's illustrated equine dermatology notes. *Veterinary Dermatology* **11**, 172-175
- WHITE, S. L. (1992) Bullous autoimmune skin disease: diagnostics, therapy, prognosis. *Proceedings of the American Association for Equine Practice* **38**, 507-513
- WOHLSEIN, P., HARPS, O. & TRAUTWEIN, G. (1994) Pemphigus foliaceus in a foal. A case history. *Tierärztliche Praxis* **22**, 151-154
- WOHLSEIN, P., TRAUTWEIN, G. & DEEGEN, E. (1993) Pemphigus in a horse. *Veterinary Dermatology* **4**, 27-32
- YAEGER, J. A. & SCOTT, D. W. (1993) The skin and appendages. In *Pathology of Domestic Animals IV*. Vol I. Ed K. V. F. Jubb. New York, Academic Press. pp 531-738